

Purpose & Objective

Previously it was shown that VSAB, the volume of gray matter that exceeds a z-score threshold when compared to a database of young healthy controls, can be helpful for distinguishing amyloid+ from amyloid- patients. In our current study we will evaluate a larger cohort of subjects along with the modification of using a probabilistic gray matter mask (GMM) for VSAB.

Methods & Materials

MRI scans from 10 subjects were segmented using FreeSurfer into GM and WM. The segmentations were transferred to corresponding florbetapir images for the same patients and transformed into template space using the florbetapir template registration. A mask was constructed for computing VSAB which includes only voxels which are at least 50% more likely to contain gray matter than white matter. 183 florbetapir PET scans were read in consensus by 3 readers, as described in Fleisher et. al (2011), and were classified as either amyloid+ or amyloid-. MIMneuro 6.3 was used without intervention to deformably register each scan to a common template space comprised of 3 florbetapir PET templates. Z-scores were computed for every voxel as compared to 74 young healthy controls within a probabilistic GMM. Z-score thresholds from 1.65 to 7 were considered for the computation of VSAB, defined as the percentage of voxels within the gray matter mask that exceeded the z-score threshold. The z-score volume threshold was defined by finding the best separation of the two groups.

Figure 1
Gray Matter Segmentation

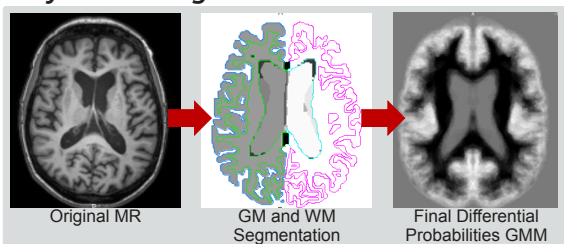


Figure 2
Z-Score Images

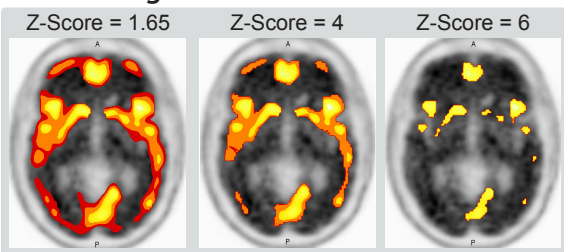
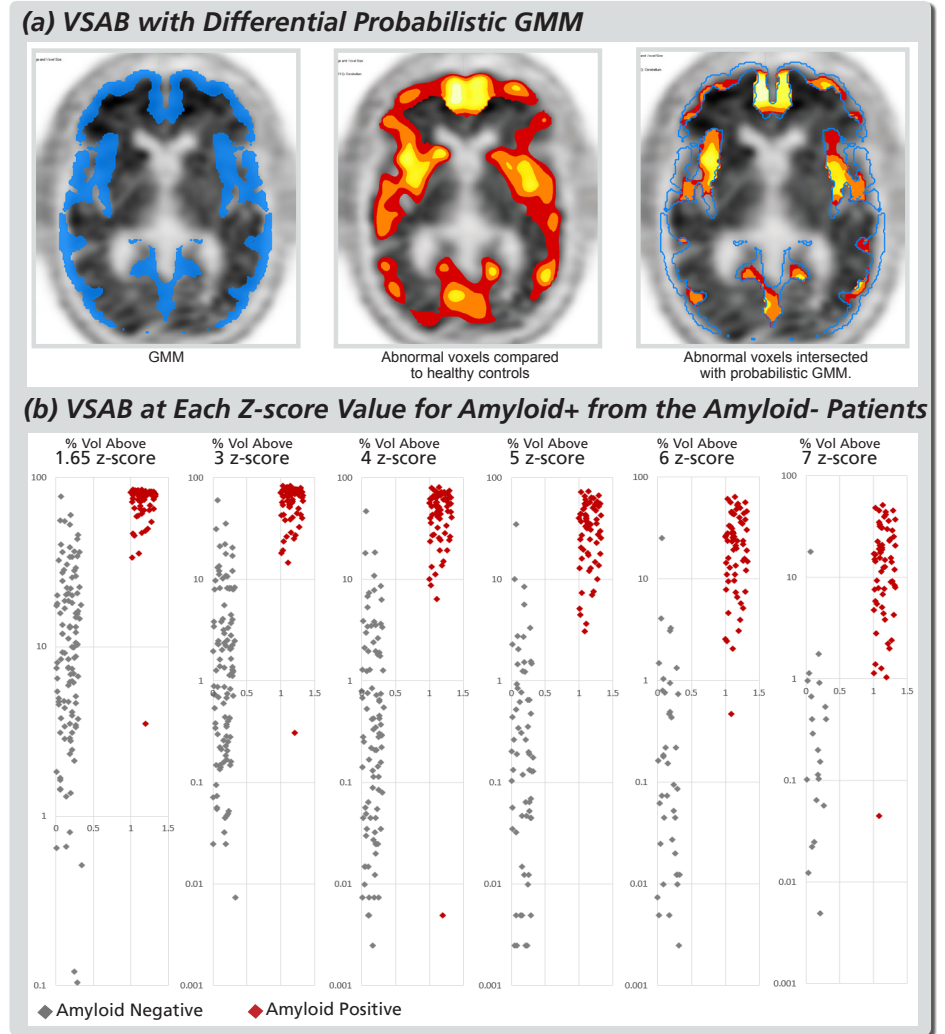


Figure 3



Results

Agreement with consensus reads for VSAB at z-score thresholds 1.65, 3, 4, 5, 6, 7 were kappa = 0.90, 0.92, 0.93, 0.92, 0.93, 0.94, respectively. The VSAB used were 45.9, 22.2, 8.6, 3.5, 1.7, 1.0 %, respectively. Using z-score 7 threshold the percent of patients classified correctly were 97.3%. For the visually positive cases, 66/68 (97.1%) were correctly classified and for the visually negative cases, 112/115 (97.4%) were correctly classified.

Table 1
Agreement with Consensus

Z-Score Thresh	VSAB (%Vol)	Kappa
1.65	45.9	.90
3	22.2	.92
4	8.6	.93
5	3.5	.93
6	1.7	.93
7	1.0	.94

Conclusion

VSAB using a probabilistic GMM was found to provide excellent agreement with expert visual assessment. The high agreement with expert visual assessment suggests that there may be value in computing voxel-level z-scores for amyloid images and that VSAB is a valuable single metric for quantitative z-assessment of amyloid images.

References

1. Amyloid Reader Training Online Program: <http://www.amyvidhcp.com/Pages/reader-training.aspx>
2. Fleisher AS, Chen K, Liu X, et al. Using Positron Emission Tomography and Florbetapir F18 to Image Cortical Amyloid in Patients with Mild Cognitive Impairment or Dementia Due to Alzheimer's Disease. Arch Neurol. 2011;68(11):1404-1411.
3. Cortical reconstruction and volumetric segmentation was performed with the FreeSurfer image analysis suite, which is documented and freely available for download online (<http://surfer.nmr.mgh.harvard.edu/>)