

# Novel extracorporeal magnetotransduction therapy with Magnetolith and high-energy focused electromagnetic extracorporeal shockwave therapy as bone stimulation therapy for scaphoid nonunion

## A case report

Karsten Knobloch, FACS, MD, PhD\* 

### Abstract

**Introduction:** The case report describes a non-invasive combination of novel Magnetolith Extracorporeal magnetotransduction therapy (EMTT) with high-energy focused extracorporeal shockwave therapy (ESWT) for scaphoid nonunion.

**Patient concern:** In March 2020, a 31-year-old male presented with significant left wrist pain with the epicenter in the radial fossa, limiting daily activities and sports. Initial injury happened in 2005 when the patient was 16-years-old which was neglected. The first scaphoid non-union surgery took place in 2012 with bone-grafting and Herbert-screw. The second revision surgery took place in December 2019.

**Diagnosis:** CT scan showed a non-healing atrophic bone graft in the scaphoid region.

**Intervention:** In March/April 2020, combined novel Magnetolith (EMTT, 8 Hertz, 6000 shots, energy level 6/8) with high-energy focused electromagnetic ESWT (0.35mJ/mm<sup>2</sup>, 4000 shots, 4 Hertz) was performed in 3 sessions on a weekly interval to accelerate bony healing.

**Outcomes:** Cone-beam CT in May 2020 (5 weeks after the last combined EMTT/ESWT treatment) revealing bony consolidation.

**Conclusion:** The combination of novel non-invasive Magnetolith (EMTT) with focused high-energy ESWT for 3 sessions on a weekly interval can significantly improve bony healing in scaphoid nonunion. To the best of my knowledge, this is the first report to apply EMTT & ESWT for scaphoid nonunion after failed surgeries.

**Abbreviations:** EMTT = extracorporeal magnetotransduction therapy; ESWT = extracorporeal shockwave therapy.

**Keywords:** extracorporeal magnetotransduction therapy, extracorporeal shockwave therapy, magnetic field, nonunion, pain, scaphoid

Written informed consent was obtained from the patient for publication of this case report and accompanying images. Since this is a single case report only, no IRB approval was necessary. No funding has been received. The author has no conflict of interest. All relevant data are within the paper and its Supporting Information files.

Supplemental Digital Content is available for this article.

All data generated or analyzed during this study are included in this published article and its supplementary information files.

Heiligerstr. 3, Hannover, Germany.

\* Correspondence: Karsten Knobloch, Heiligerstr. 3, 30159 Hannover, Germany (e-mail: Professor.knobloch@sportpraxis-knobloch.de).

Copyright © 2020 the Author(s). Published by Wolters Kluwer Health, Inc. This is an open access article distributed under the Creative Commons Attribution License 4.0 (CCBY), which permits unrestricted use, distribution, and reproduction in any medium, provided the original work is properly cited.

How to cite this article: Knobloch K. Novel extracorporeal magnetotransduction therapy with Magnetolith and high-energy focused electromagnetic extracorporeal shockwave therapy as bone stimulation therapy for scaphoid nonunion: a case report. *Med Case Rep Study Protoc* 2020;2:1(e0028).

Received: 11 September 2020 / Received in final form: 12 October 2020 / Accepted: 15 October 2020

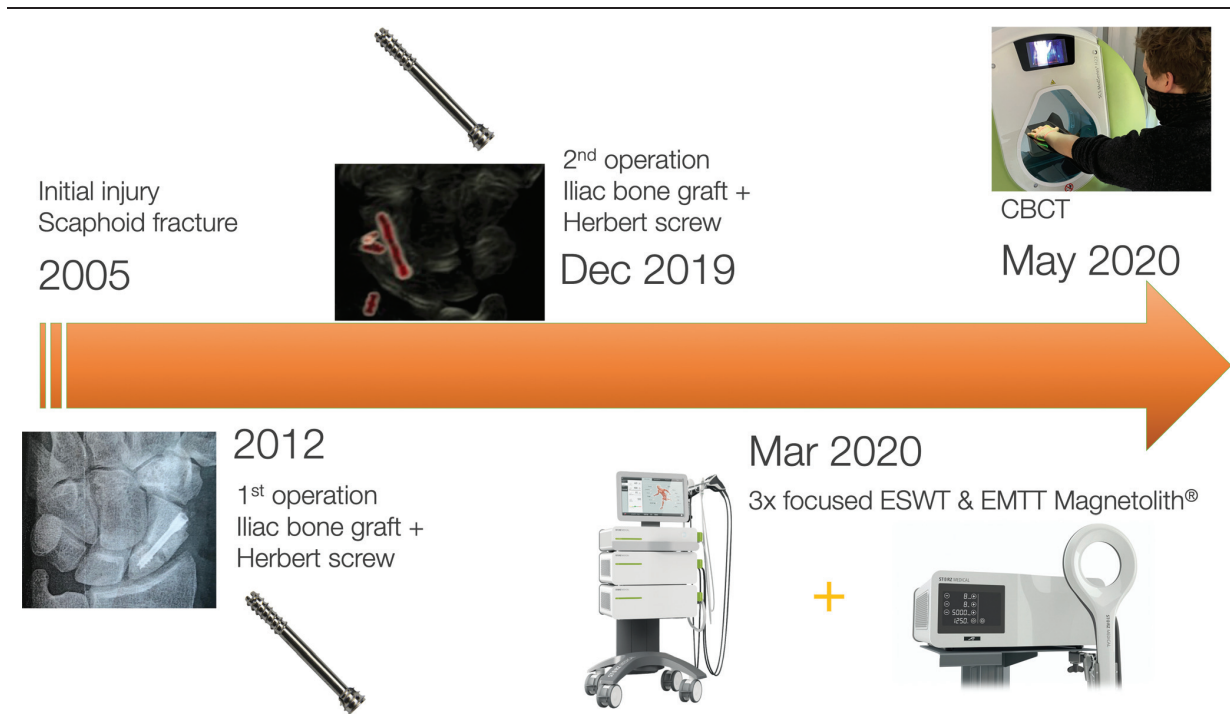<http://dx.doi.org/10.1097/MD9.000000000000028>

## 1. Introduction

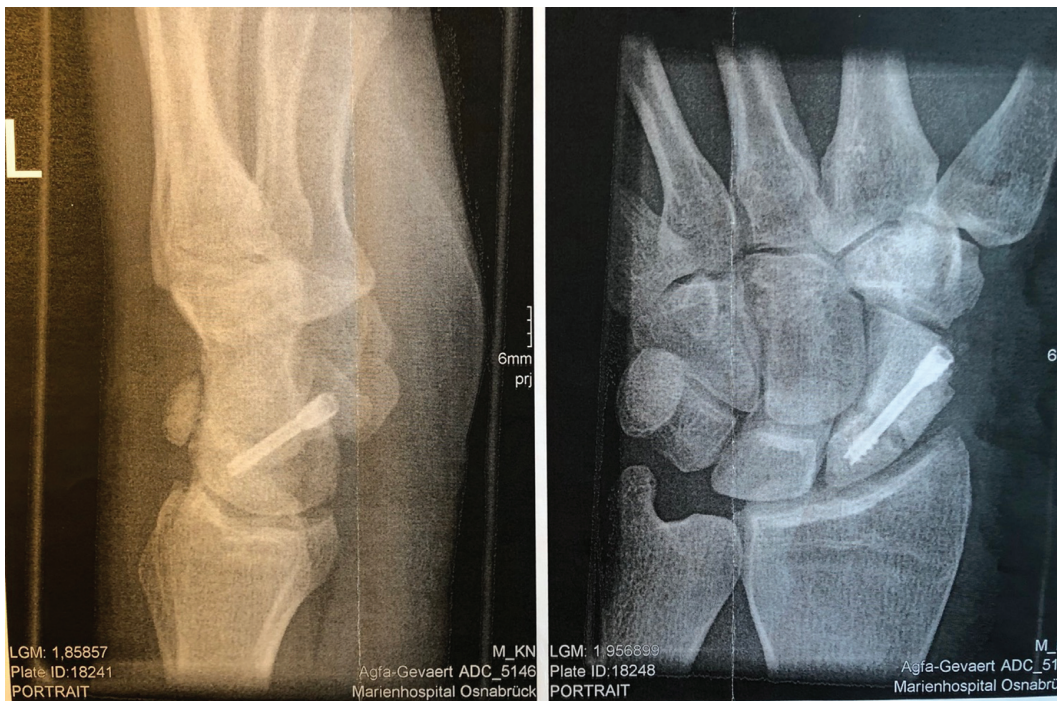
Scaphoid fractures may lead to nonunion situations, especially if not treated promptly.<sup>[1]</sup> A prolonged time to diagnosis has been reported as a contributing factor of this condition.<sup>[2]</sup> Anatomically, scaphoid perfusion of the proximal pole is retrograde via the dorsal scaphoid artery, a branch of the radial artery. Thus, scaphoid nonunions where malperfusion plays a role can more likely occur on the proximal scaphoid pole. Treatment options for scaphoid nonunion mainly focus on surgery with open reduction and internal fixation aided by either vascularized or non-vascularized bone grafting, however there is no consensus on the most appropriate treatment.<sup>[3,4]</sup>

Non-surgical therapeutic options include low-intensity pulsed ultrasound (LIPUS) as well as extracorporeal shockwave therapy (ESWT). LIPUS with intensities of 0.5 to 50 mW/cm<sup>2</sup> is considered to stimulate bone healing. A recent study<sup>[5]</sup> of 66 patients with non-healing fractures reported a 67% LIPUS overall success rate. However, in post-surgical scaphoid fractures LIPUS treatment is not effective.

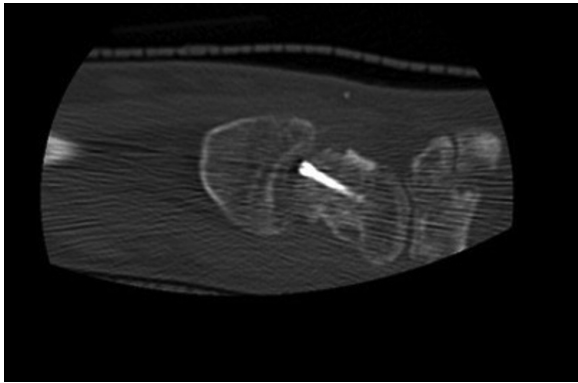
ESWT has been reported in scaphoid nonunion as early as 2000 by an Italian group. They treated 153 scaphoid fractures



**Figure 1.** Timeline of the events from the initial injury in 2005 till the treatment in March 2020 with bone stimulation therapy with high-energy focused electromagnetic ESWT and extracorporeal magnetotransduction therapy (EMTT) with Magnetolith.



**Figure 2.** Conventional X-ray after the initial nonvascularized bone grafting and Herbert screw fixation of the scaphoid nonunion in 2012.



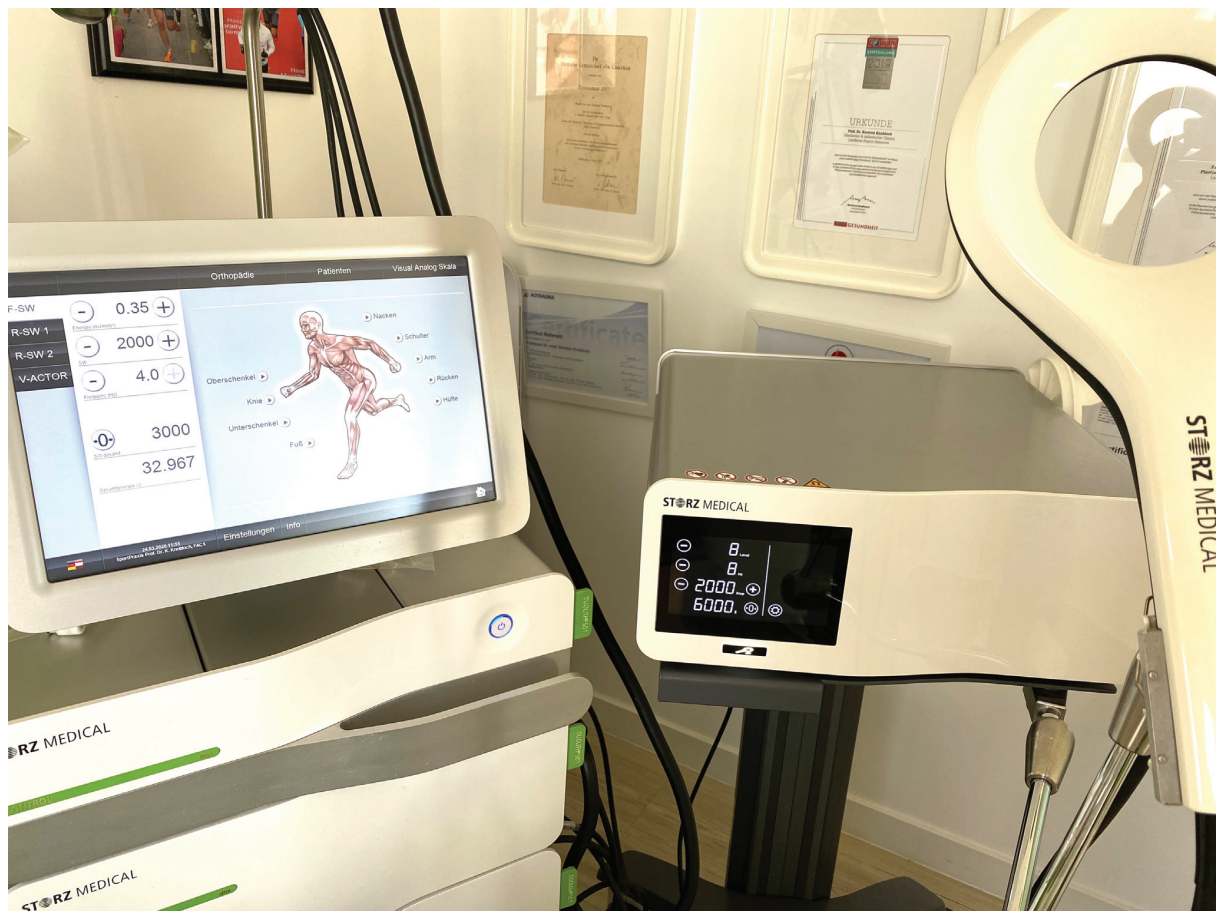**Figure 3.** Computed tomography (CT) in March 2020 after the second surgery with nonvascularized bone graft and Herbert screw fixation (revision surgery) showing persistent scaphoid nonunion.

with 4 sessions of focused electromagnetic ESWT with 4000 shots per session and  $0.5\text{mJ}/\text{mm}^2$  every third day.<sup>[6]</sup> Seven weeks later, 48% were completely healed, and 37% were partially

healed. At 16 weeks, the total healing rate was 53% and partial healing rate was 31%.

The novel Magnetolith therapy follows the principle of extracorporeal magnetotransduction therapy (EMTT), which is a noninvasive therapeutic option. EMTT is a promising new technology of treatment based on pulsed electromagnetic field (PEMF) with magnetic field strength between 10 and 80 mT and oscillating frequencies of 100 to 300 kHz. EMTT is characterized by high-frequency oscillating magnetic fields with an effective transduction performance of  $>60$  kT/s. This is in contrast to pulsed electromagnetic field (PEMF) therapy, where effective transduction performance is  $<60$  kT/s with the commercially available PEMF machines. Impulses are emitted by a high-speed generator that is released in nanoseconds with an impulse release frequency of up to 8 Hertz. The very short duration of each impulse ensures full electrophysical reaction without any temperature rise in the tissue.

This case report highlights the combination of high-energy focused electromagnetic ESWT with novel EMTT with Magnetolith for bone stimulation after 2 previous failed hand surgeries. The case is reported according to the CARE guidelines for case reports.<sup>[7]</sup>



**Figure 4.** High-energy focused electromagnetic extracorporeal shockwave therapy (ESWT, Storz Ultra by Storz Medical, Tägerwilien, Switzerland, on the left) and novel extracorporeal magnetotransduction therapy with Magnetolith (Storz Medical, Tägerwilien, Switzerland, on the right) for bone stimulation therapy in scaphoid nonunion.



**Figure 5.** Customized scaphoid cast during bone stimulation therapy.

## 2. Case presentation

A 31-year old consultant suffered a scaphoid fracture in 2005 on his left wrist when he was 16 years old, as a result of handball playing. However, this was neglected and an appropriate diagnosis of scaphoid nonunion was made only in 2011. In March 2012, he underwent the first surgery in his hand with a non-vascularized bone graft from the iliac crest and a Herbert screw.

Due to prolonged wrist pain, a second surgery in his hand (revision surgery) was performed in December 2019 with a non-vascularized iliac bone graft and a Herbert screw. In March 2020, 4 months after the revision surgery, he was admitted to my

practice due to prolonged bony healing (16 weeks) visualized by a CT scan and chief complaint of wrist pain. Risk factor analysis revealed he was a nonsmoker and non-diabetic. Physical examination in March 2020 revealed wrist pain on the radial aspect of the wrist. Pain was aggravated on dorsal extension of the wrist under load. The timeline is highlighted in Figure 1. An X-ray scan available from March 26, 2012 revealed a retrograde Herbert screw with a visible fracture line in the waist of the scaphoid (Fig. 2).

A CT scan on March 12, 2020 revealed a non-healing atrophic situation of the bone graft within the scaphoid after 2 surgeries and 2 Herbert screws (Fig. 3).

Four months after the second surgery, 3 sessions of combined high-energy focused electromagnetic extracorporeal shockwave therapy (Storz Ultra) and extracorporeal magnetotransduction therapy with Magnetolith, was performed on March 13, March 23, and April 8, 2020 (Fig. 4).

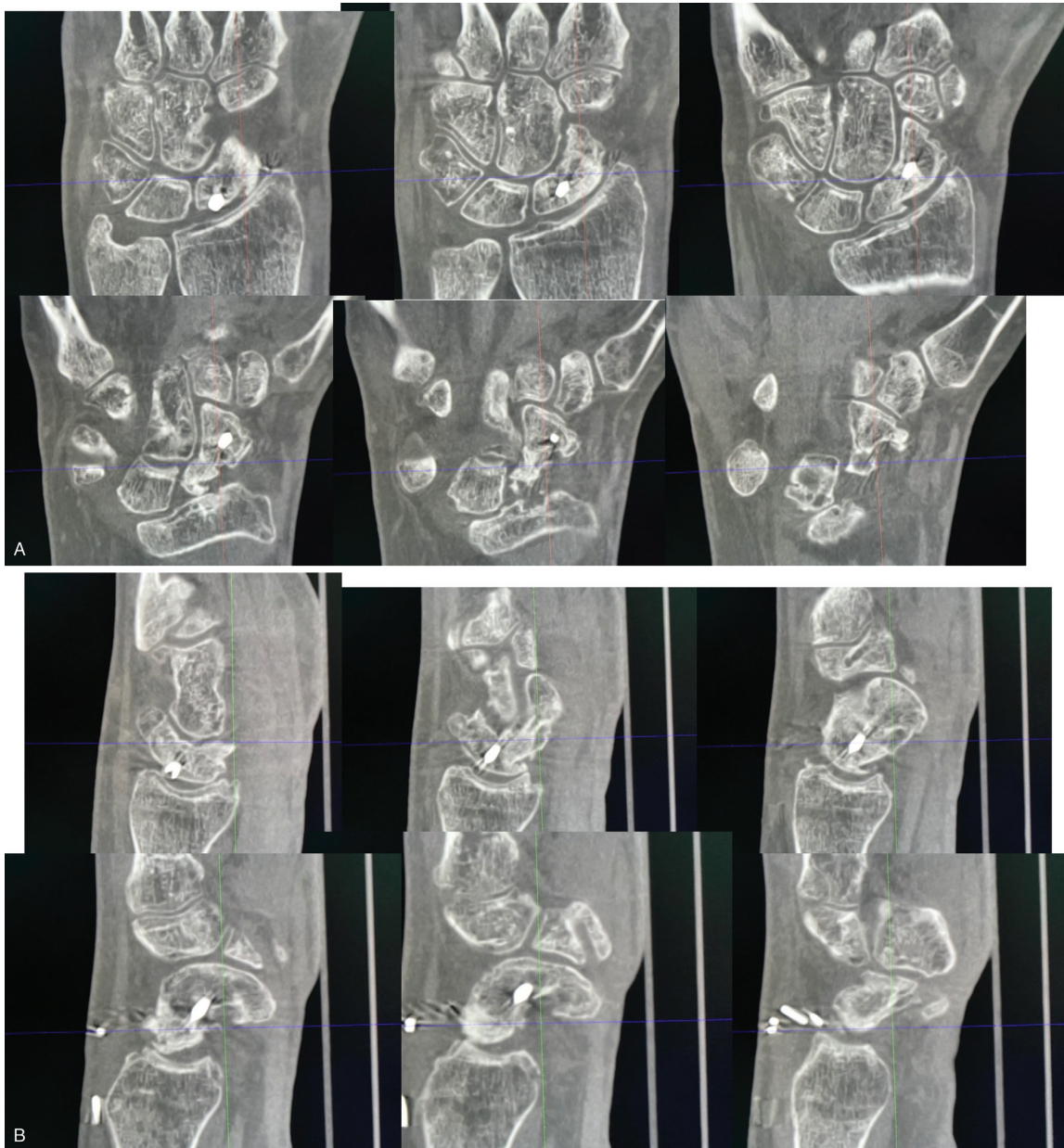
Focused electromagnetic high-energy ESWT was performed without any anesthesia using the Storz Ultra device (Storz Medical, Tägerwil, Switzerland) with an energy flux density of  $0.35\text{mJ}/\text{mm}^2$  (by definition, high-energy corresponding to 24 kV) with 4000 impulses per session with a Storz standoff number of 2. The scaphoid nonunion line was visualized by high-resolution ultrasound both from the palmar and dorsal aspect of the wrist. Focused high-energy ESWT was then performed with 2000 impulses from the palmar aspect and 2000 impulses from the dorsal aspect to the scaphoid.

Extracorporeal magnetotransduction therapy (EMTT) was performed immediately after the high-energy focused ESWT with Magnetolith (Storz Medical, Tägerwil, Switzerland) with energy level 8, 8 Hertz and 6000 impulses per session. No complications of either ESWT or EMTT treatment were evident, and there was no bleeding or hematoma.

A customized plaster was worn until May 14, 2020.



**Figure 6.** Cone beam computed tomography (CBCT) with Sophisticated computer system MedSeries H22 system in May 2020.



**Figure 7.** A/B/C: Scaphoid 3-dimensional imaging with metal suppression with the SCS MedSeries H22 system demonstrating scaphoid bony consolidation in all 3 planes without signs of lysis or osteonecrosis.

After the therapeutic intervention with 3 sessions of combined focused ESWT and EMTT, a cone beam CT scan of the wrist was performed with the MedSeries H22 system on May 14, 2020, which was performed 5 weeks after the last bone stimulation therapy (Figs. 5 and 6). This system allows to run metal-suppression sequences for detailed analysis of the scaphoid bone stock despite the Herbert screw with its inherent metallic artefacts.

Six months after the second surgery and 8 weeks after the first bone stimulation therapy with combined high-energy focused

electromagnetic ESWT and EMTT with Magnetolith, the scans revealed complete bony consolidation within 8 weeks after bone stimulation therapy with a reasonable scaphoid bone stock around the Herbert screw in all 3 planes. Metallic artifacts were reduced by the Sophisticated computer system H22 MedSeries system substantially (Fig. 7A–C).

No adverse events were noted during or after the bone stimulation therapy. The patient was very satisfied with the bone stimulation treatment. The wrist cast was removed after the CBCT and the patient started gradually with strengthening

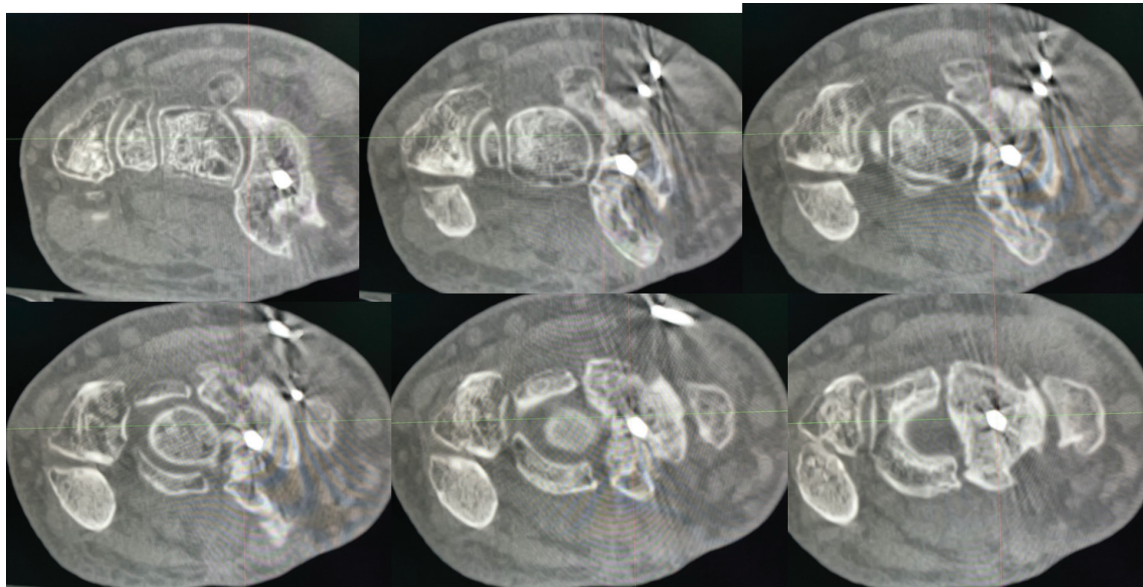


Figure 7. (Continued).

exercises using the TheraBand FlexBar with supination and pronation with straight elbows with 3 x 15 repetitions twice a day for 3 months to strengthen the forearm and hand muscles.

### 3. Discussion

This is the first report on the combination of high-energy focused electromagnetic ESWT and novel Magnetolith EMTT treatment for bone stimulation therapy after a failed scaphoid revision surgery. Accelerated bony consolidation could be visualized by cone beam CT with the Sophisticated computer system MedSeries H22 system allowing metallic-artefact-suppression sequences after failed revision scaphoid surgery.

The beneficial use of focused high-energy ESWT alone has been reported as early as 2000<sup>6</sup>. Scaphoid perfusion is improved by high-energy-focused ESWT, as reported recently by Laser-Doppler flowmetry after piezoelectric-focused ESWT (0.3mJ/mm<sup>2</sup>, 8 Hertz, 1000 impulses).<sup>[8]</sup> A single piezoelectric focused ESWT session increased the scaphoid blood flow by 39% within 30 minutes. Scaphoid bony healing in nonunion situations with focused high-energy ESWT alone has reported a success rate of 70% to 80%<sup>[9,10]</sup> in a 6-month follow-up period. Success factors in scaphoid nonunion ESWT involve timing of initiation of focused high-energy ESWT; the sooner, the better as well as a simultaneous scaphoid cast during the treatment.<sup>[11]</sup>

This aforementioned benefit of focused high-energy ESWT is based on the high and focused energy transmitted to the bony nonunion, which is mediated by mechanotransduction.<sup>[12,13]</sup> High-energy energy is defined as an energy flux density >0.25mJ/mm<sup>2</sup>, which is only achieved by focused ESWT and not by radial pressure waves.

The novel EMTT with Magnetolith can add clinically beneficial effects to the focused ESWT. In a randomized trial<sup>[14]</sup> on nonspecific LBP comparing standard therapy (physiotherapy with core stabilization plus non-opiate analgesics) with or

without additional EMTT therapy with 88 patients randomized 1:1, the combination group was superior in terms of pain reduction on the visual analog scale with an improvement in the Oswestry disability index score. In rotator cuff tendinopathy, an RCT underpins this observation with superior results when combining focused high-energy ESWT and EMTT.<sup>[15]</sup>

To date, no data have been published on the combination of focused ESWT and novel EMTT for bone stimulation, which is why this case report is unique. EMTT is characterized by high-frequency oscillating magnetic fields with an effective transduction performance of >60kTesla/second (kT/s), which is physically different from pulsed electromagnetic field (PEMF) therapy machine with effective transduction performance significantly lower than 60kT/s.

PEMF has been reported to inhibit cellular apoptosis and modulate cytoskeletal distribution in osteocytes.<sup>[16]</sup> Clinically, a recent review<sup>[17]</sup> of 22 studies (1468 participants) reported that PEMF increases the healing rate in fractures and accelerates the healing time. However, larger scale randomized controlled trials are mandatory in this regard, especially in terms of optimal timing, amplitude, and duration of the PEMF effects.

This case highlights the potential of the combination of focused high-energy electromagnetic ESWT and novel EMTT. Future prospective trials are warranted to elucidate its role in the field of sports medicine in stress fractures as well as an adjunct after surgery for rapid rehabilitation in high-level athletes after fractures.

To conclude, the combination of novel noninvasive Magnetolith extracorporeal magnetotransduction therapy (EMTT) with focused high-energy electromagnetic ESWT for 3 sessions on a weekly interval can significantly accelerate bony healing in scaphoid nonunion. This is the first report to apply novel EMTT and high-energy focused ESWT for scaphoid nonunion after 2 scaphoid surgeries with substantial acceleration of scaphoid bone healing.

## Author contributions

KK did the entire case report.

## References

- [1] Prabhakar P, Wessel L, Nguyen J, et al. Factors associated with scaphoid nonunion following early open reduction and internal fixation. *J Wrist Surg* 2020;92:141–9.
- [2] Peterson SH, Donoughe JS, O’Neal D, et al. Streamlining definitive care for occult scaphoid fractures: a retrospective review of the workup of scaphoid nonunions and applying lessons learned. *Mil Med* 2020;185:e958–62.
- [3] Pinder RM, Brkljac M, Rix L, et al. Treatment of scaphoid nonunion: a systematic review of the existing evidence. *J Hand Surg Am* 2015;40:1797–805.
- [4] Borgers CS, Ruschel PH, Pignataro MB. Scaphoid reconstruction. *Orthop Clin North Am* 2020;51:65–76.
- [5] Bawale R, Segmeister M, Sinha S, et al. Experience of an isolated use of low-intensity pulsed ultrasound therapy on fracture healing in established nonunions: a prospective case series. *J Ultrasound* 2020; doi: 10.1007/s40477-020-00464-9.
- [6] Corrado B, Russo S, Gigliotti S, et al. Shockwave treatment for nonunions of the carpal scaphoid. *Musculoskeletal Shockwave Therapy 2000*;Greenwich Medical Media Ltd, ISBN 1-844110-058-7.
- [7] Riley DS, Barber MS, Kienle GS, et al. CARE guidelines for case reports: explanation and elaboration document. *J Clin Epidemiol* 2017; 89:218–35.
- [8] Schlessner S, Song J, Stang FH, et al. Blood flow in the scaphoid is improved by focused extracorporeal shockwave therapy. *Clin Orthop Relat Res* 2020;478:127–35.
- [9] Fallnhauser T, Wilhelm P, Priol A, et al. Extracorporeal shockwave therapy for the treatment of scaphoid delayed union and nonunion: a retrospective analysis examining the rate of consolidation and further outcome variables. *Handchir Mikrochir Plast Chir* 2019;51:164–70.
- [10] Quaddlbauer S, Pezzeri C, Beer T, et al. Treatment of scaphoid waist nonunion by one, two headless compression screws or plate with or without additional extracorporeal shockwave therapy. *Arch Orthop Trauma Surg* 2019;139:281–93.
- [11] Stojadinovic A, Potter BK, Eberhardt J, et al. Development of a prognostic native Bayesian classifier for successful treatment of nonunions. *J Bone Joint Surg Am* 2011;93:187–94.
- [12] D’Agostino MC, Craig K, Tibalt E, et al. Shockwave as biological therapeutic tool: from mechanical stimulation to recovery and healing, through mechanotransduction. *Int J Surg* 2015;24(Pt B):147–53.
- [13] Schaden W, Mittermayr R, Haffner N, et al. Extracorporeal shockwave therapy (ESWT)-first choice treatment of fracture non-unions? *Int J Surg* 2015;24(Pt B):179–83.
- [14] Krath A, Klüter T, Stukenberg M, et al. Electromagnetic transduction therapy in non-specific low back pain: a prospective randomized controlled trial. *J Orthop* 2017;14:410–5.
- [15] Klüter T, Krath A, Stukenberg M, et al. Electromagnetic transduction therapy and shockwave therapy in 86 patients with rotator cuff tendinopathy: a prospective randomized controlled trial. *Electromagn Biol Med* 2018;37:175–83.
- [16] Wang P, Tang C, Wu J, et al. Pulsed electromagnetic fields regulate osteocyte apoptosis, RANKL/OPG expression, and its control of osteoclastogenesis depending on the presence of primary cilia. *J Cell Physiol* 2019;234:10588–601.
- [17] Peng L, Fu C, Xiong F, et al. Effectiveness of pulsed electromagnetic fields on bone healing: a systematic review and meta-analysis of randomized controlled trials. *Bioelectromagnetics* 2020;41:323–37.