

# Extracorporeal Shock Wave Therapy for Nonunion of the Tibia

Eric A. Elster, MD, FACS,\*† Alexander Stojadinovic, MD, FACS,‡ Jonathan Forsberg, MD,\*¶  
Scott Shawen, MD,|| Romney C. Andersen, MD,|| and Wolfgang Schaden, MD§

**Objectives:** Delayed and nonunion of the tibia are not uncommon in orthopaedic practice. Multiple methods of treatment have been developed with variable results. The objective of this study was to define disease-specific and treatment-related factors of prognostic significance in patients undergoing shock wave therapy for tibia nonunion.

**Design:** Retrospective analysis.

**Patients:** One hundred ninety-two patients treated with extracorporeal shock wave therapy (ESWT) at a single referral trauma center, AUVA-Trauma Center Meidling, a large single-referral trauma center located in Vienna, Austria, in an attempt to determine the feasibility and factors associated with the use of ESWT in the treatment for tibia nonunion.

**Intervention:** ESWT coupled with posttreatment immobilization, external fixation, or ESWT alone.

**Main Outcome Measures:** Fracture healing, overall healing percent, and factors associated with ESWT success or failure.

**Results:** At the time of last follow up, 138 of 172 (80.2%) patients have demonstrated complete fracture healing. Mean time from first shock wave therapy to complete healing of the tibia nonunion was  $4.8 \pm 4.0$  months. Number of orthopaedic operations ( $P = 0.003$ ), shock wave treatments ( $P = 0.002$ ), and pulses delivered ( $P = 0.04$ ) were significantly associated with complete bone healing. Patients requiring multiple (more than one) shock wave treatments versus a single treatment had a significantly lower likelihood of fracture healing ( $P = 0.003$ ). This may be attributable to the finding that a significantly greater proportion of patients with multiple rather than single ESWT treatments had three or more prior orthopaedic procedures (more than one ESWT, 63.9% versus one ESWT, 23.5%;  $P < 0.001$ ).

**Conclusions:** ESWT is a feasible treatment modality for tibia nonunion.

**Key Words:** ESWT, nonunion, fracture

(*J Orthop Trauma* 2010;24:133–141)

## INTRODUCTION

Nearly 1.5 million of the 6 million fractures treated each year in the United States involve long bones, and nearly one third of these long bone fractures involve the tibia.<sup>1–3</sup> A recent meta-analysis estimated the combined prevalence of tibia nonunions at 2.5% making it the most frequent long bone nonunion.<sup>4</sup> The lack of surrounding muscle on the anterior medial border of the tibia is thought to make it more susceptible to nonunion. Tibia nonunion, a result of cessation of periosteal and endosteal healing without fracture bridging, contributes significantly to functional limitations, treatment-related morbidity, and healthcare costs. Tibia nonunions are notoriously refractory to treatment and often require multiple interventions over a period of months to years. The result is a large financial burden in both direct costs reflected by hospital and trauma system resource consumption as well as indirect personal costs of rehabilitation and lost productivity resulting from pain, functional deficits, and immobility.<sup>5,6</sup>

The treatment of tibia nonunion remains highly individualized, complex, and demanding. Treatment options depend on the mechanical and biologic nature of the nonunion and include stabilization when indicated, correction of deformity, eradication of infection, soft tissue coverage, and staged bone grafting.<sup>7–9</sup> The prolonged natural history of tibia nonunions has engendered innovative and alternative treatment approaches, including mechanical and molecular interventions in the form of nail dynamization, exchange nailing,

Accepted for publication June 11, 2009.

From the \*Combat Wound Initiative, National Naval Medical Center, Bethesda, MD; †Naval Medical Research Center, Silver Spring, MD; ‡Combat Wound Initiative, Walter Reed Army Medical Center, Washington, DC; §AUVA-Trauma Center Meidling, Vienna, Austria; ||Orthopaedic Surgery Service, Walter Reed Army Medical Center, Washington, DC; and ¶Department of Orthopaedic Surgery, National Naval Medical Center, Bethesda, MD.

Drs. Elster and Stojadinovic contributed equally to this work.

In the previous 2 years, no author has received financial compensation, including salaries, consultant or advisory positions, speaker bureaus, lecture fees, grant support, equity payments, patents, advisor to investment companies, and expert witness testimony except Dr. Wolfgang Schaden. Dr. Schaden has received compensation in exchange for his participation in the preparation of this article or in exchange for supplying the data contained within this article. Dr. Schaden is a minority member of a US company that holds an equity position in a foreign manufacturer that produces a product that may be competitive to the medical device referenced herein.

The medical device referenced in this article has received premarket approval for chronic lateral epicondylitis and plantar fasciitis. The medical device is not approved for nonunions.

The views expressed in this article are those of the authors and do not reflect the official policy of the Department of the Army, Department of the Navy, the Department of Defense, or the US Government.

Reprints: Eric A. Elster, MD, FACS, CDR MC USN, Combat Casualty Care, NMRC, Department of Surgery, NNMRC Bethesda, Assistant Professor of Surgery, Uniformed Services University, 503 Robert Grant Ave, Silver Spring, MD 20910 (e-mail: eric.elster@med.navy.mil).

Copyright © 2010 by Lippincott Williams & Wilkins

bone growth stimulation with electrical current and ultrasound, external stabilization with compression, bone grafting procedures, orthobiologic enhancement with recombinant osteogenic proteins, and shock wave therapy.<sup>2,3,10-17</sup> Applied mechanical stimuli to the nonunion in the form of pulsed electromagnetic waves and low-intensity ultrasound have shown inconsistent results despite obligatory extended treatment periods, particularly with atrophic and infected nonunions.<sup>18-24</sup>

A promising technology, extracorporeal shock wave therapy (ESWT), has been used to treat various musculoskeletal afflictions, including calcific tendinopathy of the rotator cuff, lateral epicondylitis, and chronic plantar fasciopathy.<sup>25-33</sup> Mechanistic studies support a positive influence of shock waves on osseous biology through enhanced biomechanical properties (increased bone mass and strength) and angiogenesis (shock wave stimulated osteoblast vascular endothelial growth factor-A and ERK-dependent activation of hypoxia-induced factor-1 alpha) in addition to augmented osteogenic differentiation of mesenchymal stem cells (through transforming growth factor- $\beta$ -1 and superoxide induced ERK-dependent activation of osteogenic transcription, CBFA1).<sup>34-39</sup>

Preliminary clinical data suggested that biophysical stimulation through high-energy shock wave therapy might be a safe and effective alternative treatment for delayed and nonunion of long bones.<sup>40-42</sup> Our early experience with tibia nonunions demonstrated a favorable response and side effect profile with ESWT.<sup>42</sup> The current analysis is an expansion of a previous study and was conducted on a larger, well-characterized patient cohort with tibia nonunions that were treated consecutively and followed at a single institution specializing in the treatment of long bone nonunion with ESWT.<sup>42</sup> In this study, we aim to define disease-specific and treatment-related factors of prognostic significance in patients undergoing shock wave therapy for tibia nonunion.

## PATIENTS AND METHODS

### General

This retrospective study analyzed 192 consecutive patients with tibia nonunions treated at AUVA-Trauma Center during the time period December 1998 to June 2004. These constituted all patients with nonunions seen in this center during this time period. The study was approved by the Institutional Review Board and written informed consent provided by each study participant.

### Clinical and Radiologic Assessment

Clinical covariates investigated in this study included patient age, gender, primary presentation, and involved segment of tibia. Fracture location was defined according to proximal metaphyseal, middiaphyseal, and distal third of the tibia. Fracture healing was assessed on the basis of clinical and radiographic criteria. Clinical assessment for nonunion included pain on weightbearing, pain on palpation or manual bending of the fracture site, or mobility of the fracture site. Radiographic assessment and response to treatment was made primarily with anterior-posterior and lateral radiographs. Radiographs were taken at a minimum on clinical presentation and then at 1, 3, and 6 months post-ESWT. Radiographic

variables assessed included callus presence and size, bony trabecular bridging, and progressive opacification of the fracture line. Successful healing outcome was determined by re-establishment of cortical continuity on three of four cortices at a minimum. Computed tomography (CT) was also obtained for selected cases in which plain radiographs failed to assess adequately the quality of fracture union. Those fractures that demonstrated insufficient healing on CT were included in the study. Subsequent CT scans and/or stress radiographs were obtained when fracture healing was difficult to assess on plain radiographs, again with successful healing determined by re-establishment of cortical continuity on at least three of four cortices. Magnetic resonance imaging was used to evaluate suspected infected nonunions to assess for osteomyelitis, abscess, related sinus tracts, and sequestra. Magnetic resonance imaging was not used for assessment of bone healing. Routine laboratory values such as white blood cell count, erythrocyte sedimentation rate, and C-reactive protein were used to both determine the presence of and assess the adequacy of treatment of osteomyelitis. Plain radiographs were evaluated by board-certified trauma surgeons, whereas CT and magnetic resonance imaging studies were evaluated independently by board-certified radiologists experienced with osseous pathology and radiology.

### Demographics and Definitions

We categorized nonunion based on the date of the fracture injury. Nonunion was defined as a fracture that: 1) has failed to demonstrate cortical continuity on three of four cortices despite operative or nonoperative intervention for 6 months or more; or 2) showed no radiographic changes for 3 consecutive months and was associated with inability to bear weight on the affected extremity, pain on palpation, or motion at the fracture site 6 months posttrauma.

This definition of nonunion was based on not only local practice referral guidelines, but also based on review by the US Department of Health and Human Services Technology Assessment of bone growth-stimulating devices.<sup>44</sup>

Tibia fractures were categorized as open or closed, and the etiologic basis of the nonunion was defined as fracture (nonsurgical traumatic disruption of the tibia) or osteotomy (surgical division or segmental resection of the tibia). Fractures were characterized according to radiographic correlates of underlying biology.<sup>45</sup> Hypertrophic nonunions were those with seemingly viable, well-perfused bone ends demonstrating abundant callus formation but inadequate mechanical stability. Atrophic nonunions were those with impaired osseous biology evident as diminished callus formation or osteopenia on radiographs. Infected nonunions were defined by clinical presentation (fever, open draining sinus, local erythema, edema, callor), laboratory evaluation (leukocytosis, elevated erythrocyte sedimentation rate, C-reactive protein, and positive bacteriology or histology), and/or radiologic findings (sequestra, progressive bone loss).

### Treatment

The majority of patients referred to our institution for tibia nonunion had one or more prior orthopaedic operations and/or adequate immobilization; hence, the population is

referral-based and represents largely those with fractures refractory to surgical treatment. The principal aim of ESWT was fracture union in anatomic position with restoration of function. Potential study subjects with coagulopathy, non-unions in proximity to the epiphyseal growth plate, malignant tumor in the shock wave focus, active infection (fever greater than 38°C, C-reactive protein greater than 5 mg/dL, white blood cell count greater than 12,000 K/UL), and/or pregnancy were not treated with ESWT. Inclusion criteria were those patients with tibia fractures and nonunion referred to the Trauma Center after failure of previous therapy based on the treatment patterns of the referring orthopaedic surgeons.

ESWT was administered using the OssaTron device (High Medical Technologies, Lengwil, Switzerland). Treatment was administered under general or regional anesthesia after operative intervention for the associated wound, infection, or fracture (if indicated). Patients were positioned on the operating table such that the fracture line was clearly visualized in the anterior–posterior fluoroscopic projection. The extremity to be treated was placed in such a way that the ESWT head could be positioned to focus the shock wave at the fracture site with the simultaneous use of an image intensifier (BV 25; Philips, Eindhoven, The Netherlands). The ESWT trajectory was chosen to avoid nearby neurovascular structures. The focal point was confirmed to target the fracture site using fluoroscopy (Fig. 1). The total number of pulses was divided equally along the proximal and distal margins of the nonunion. If shock wave-altering implants was present at the fracture point, the shock wave direction was selected in such a way that the implants did not shield the energy from the fracture.

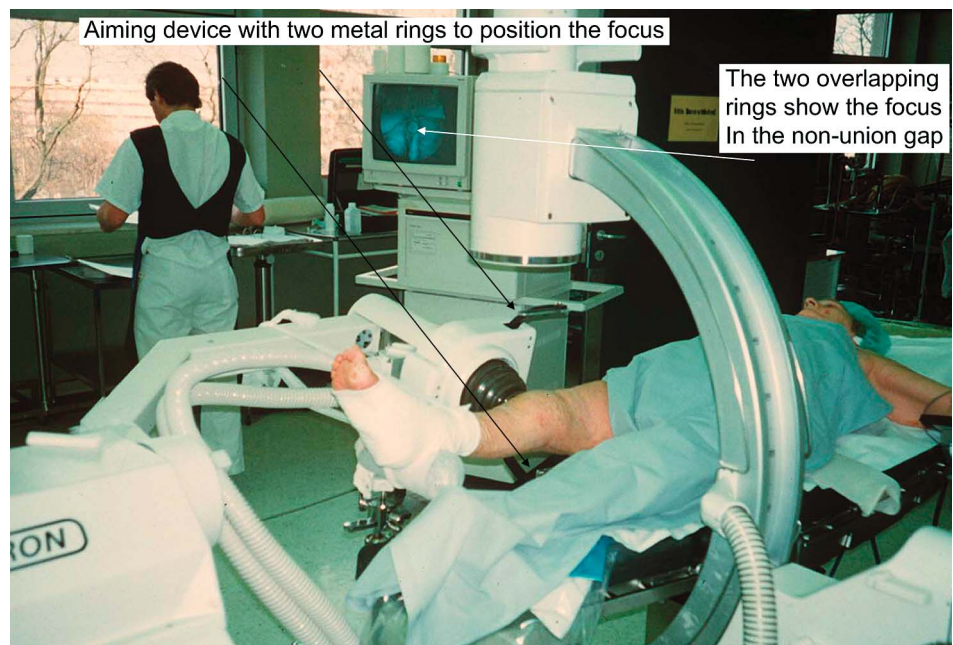
Fractures were treated with a maximum of 12,000 pulses (median, 4000 pulses) using a voltage of 26 to 28 kV for all treatments corresponding to an energy flux density 0.38 to 0.40 mJ/mm<sup>2</sup>. Treatment lasted approximately 20 to 60

minutes, directly proportional to the pulse sequences delivered. ESWT intensity applied was selected initially up to 12,000 pulses with subsequent decrease to 4000 pulses after internal review of outcomes at various pulse dose intensities and when other preclinical studies demonstrated an optimal treatment effect at a dose of 4000 pulses.<sup>41</sup>

After ESWT, the limb was treated in one of three ways: immobilization with a plaster cast or plastic splint (n = 174), placement of an external fixator (n = 10) in cases in which the nonunion had excessive mobility (greater than 15° of angulation on active fluoroscopic examination), or no additional immobilization given implant stability (n = 8). Plastic splints were chosen for multiply injured patients as well as elderly patients because of their lighter weight and greater comfort. The duration of immobilization (up to 12 weeks) was not standardized and was selected individually based on the fracture location and classification, fracture gap and stability, lower extremity alignment, and presence of underlying infection. Patients without fracture mobility were treated with either immobilization or partial to no weightbearing for 3 to 6 weeks.

## Data

The primary outcome was fracture healing. Fracture healing was defined as patient ability to bear full weight on the affected limb, absence of pain at the fracture site on manual bending or compression, and radiographic re-establishment of cortical continuity on three of four cortices with increasing bony trabecular bridging the fracture site on plain radiographs. For CT scans, fracture healing was determined to be successful if trabecular bridging of the fracture site was seen in at least three of four cortices. Time to healing was assessed from the date of the first ESWT to the date of documented fracture healing. The length of the follow-up period was calculated from the time of last orthopaedic operation (or time of injury



**FIGURE 1.** Positioning of extracorporeal shock wave therapy. Patients were positioned on the operating table such that the fracture line was clearly visualized in the anterior–posterior fluoroscopic projection. The extremity to be treated was placed to focus the shock wave at the fracture site with the simultaneous use of an image intensifier. The focal point was confirmed to target the fracture site using fluoroscopy.



in those without operation) to the date of last follow up after completion of ESWT to capture the entire study period.

## Statistics

Summary statistics were obtained using established methods. Continuous variable means are reported with standard deviations. Associations between categorical factors were studied using contingency table analysis (Fisher exact test [for small expected values] or Pearson  $\chi^2$  test, as appropriate). Statistical comparisons between continuous variables were performed with analysis of variance. The clinical outcome studied fracture healing. Statistical analysis was performed using JMP and SAS software (JMP and SAS, Cary, NC). Significance was determined by a *P* value <0.05.

## RESULTS

### Study Population

Between January 1990 and February 2004, 192 predominantly male (*n* = 140) patients with a tibial nonunion after fracture (*n* = 185) or osteotomy (*n* = 7) were referred to Trauma Center Meidling. Mean age for the study population was  $44.6 \pm 14.4$  years (median, 44 years; range, 16–90 years).

**TABLE 1.** Orthopaedic Procedures Performed Before Initiation and After Completion of Shock Wave Therapy for Delayed Union and Nonunion of the Tibia

Pre-ESWT Procedures			
Patients having pre-ESWT orthopaedic operations ( <i>n</i> = 175)*			
Fixation		Miscellaneous Procedures	
External fixation	54	Angular correction	7
Internal, intramedullary	91	Fibular osteotomy	11
Internal, extramedullary	69	Débridement of osteomyelitis	9
Casting		Dynamization	9
Plaster cast†	88	Myocutaneous free flap	8
Bone graft		Soleus or gracilis flap	4
Autograft	41	Fasciotomy	3
		Split-thickness skin graft	2
		Segmental bone transfer	2
		Vascular repair	2
		Human tibial allograft	1
Concurrent ESWT Procedures			
Patients having concurrent procedures at the time of ESWT ( <i>n</i> = 33)			
Dynamization	11	Hardware removal (external fixation, screw, wire)	7
External fixation	4	Fibular osteotomy	8
Angular correction	3	Plaster casting†	116
Hardware Present at ESWT			
Patients with hardware present at time of ESWT ( <i>n</i> = 127)			
Tibial nail	73	Screws	9
Plate and screws	30	Screws and cerclage wire	4
External fixator	9	Cerclage wire	2

\*Number of patients with prior procedures.

†Not included in procedure count.

ESWT, extracorporeal shock wave therapy.

## Pathology

Nearly two thirds of the patients (*n* = 120) had closed nonunions and 70% of all nonunions involved the mid-diaphysis (proximal = 20 [10.4%]; midshaft = 135 [70.3%]; distal = 37 [19.3%]). Forty percent of the study populations presented with atrophic nonunions (atrophic = 78 [40.6%]; hypertrophic = 73 [38.0%]; infected = 41 [21.4%]).

## Operative and Shock Wave Interventions

Over 90% (*n* = 175) of patients underwent one or more orthopaedic operative interventions, including periods of immobilization before focused shock wave therapy (mean,  $2.4 \pm 1.9$ ; median, 2; range, 1–10). These are summarized in Table 1.

Most patients had one shock wave treatment (*n* = 153 [79.7%]), 29 (15.1%) had two, and nine (4.7%) underwent three treatments. One patient was treated on four occasions with ESWT. Mean total shock wave dose administered for the study population was  $5510 \pm 3610$  (median, 4000; range, 2000–12,000) impulses at energy flux density of 0.38 to 0.40 mJ/mm<sup>2</sup>. Thirty-three (17.2%) patients underwent subsequent orthopaedic operative procedures, primarily dynamization (*n* = 11), hardware removal (*n* = 7), or external fixation (*n* = 4) as shown in Table 1. At final post-ESWT follow up, 28 of these 33 (84.8%) patients who underwent post-ESWT operative procedures demonstrated complete fracture healing.

## Patient Follow Up and Fracture Healing

Twenty of 192 patients have incomplete follow-up information and were not included in the subsequent analysis. Hence, the study population is based on 172 patients with complete treatment and follow-up information (Table 2).

At the time of last follow up, 138 of 172 (80.2%) patients have demonstrated complete fracture healing. Mean time from injury to first ESWT was  $16.8 \pm 27.9$  months. Mean time from last orthopaedic procedure to first ESWT was  $10.1 \pm 14.0$  months. Mean time from injury to last follow up was  $24.7 \pm 28.3$  months and from last orthopaedic procedure to last clinic visit was  $17.9 \pm 14.7$  months. Importantly, mean time from first shock wave therapy to complete healing of the tibia nonunion was  $4.8 \pm 4.0$  months. Representative radiographs of two patients (atrophic and hypertrophic nonunions) treated with ESWT are shown in Figures 2 and 3.

There were no major adverse side effects associated with shock wave therapy or the subsequent period of immobilization. Typical well-established minimal treatment-related side effects were observed infrequently and appeared to be dose-related: local edema, cutaneous petechial hemorrhage, and subcutaneous hematoma (range, 1–5 mm in greatest dimension). Local soft tissue edema, petechiae, and hematomas in the treated field resolved spontaneously without incident within 3 to 7 days. No worsening in established chronic infection was observed during ESWT and posttreatment follow up.

## Analysis of Prognostic Factors Influencing Fracture Healing

Number of orthopaedic operations (*P* = 0.003), shock wave treatments (*P* = 0.002), and pulses delivered (*P* = 0.04)

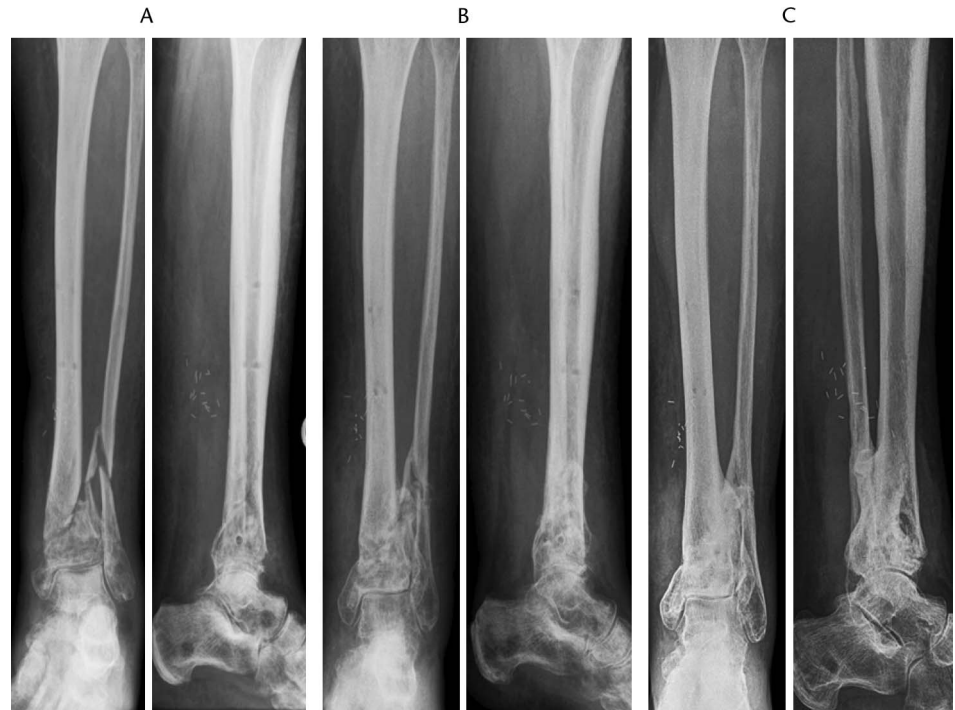**TABLE 2.** Patient, Tibia Fracture, and Treatment Characteristics (n = 172)

Characteristic	Number = 172	Healed (n = 138;80.2%)	Not Healed (n = 34;19.8%)	P
Mean		44.8 ± 14.5	45.4 ± 13.7	0.97*
Gender				0.42†
Male	122	96 (78.7%)	26 (21.3%)	
Female	50	42 (84.0%)	8 (16.0%)	
Tibia category				0.28†
Open	62	47 (75.8%)	15 (24.2%)	
Closed	110	91 (82.7%)	19 (17.3%)	
Tibia location				0.34†
Proximal	20	18 (90.0%)	2 (10.0%)	
Midshaft	117	94 (80.3%)	23 (19.7%)	
Distal	35	26 (74.3%)	9 (25.7%)	
Etiology				0.70†
Fracture	165	132 (80.0%)	33 (20.0%)	
Osteotomy	7	6 (85.7%)	1 (14.3%)	
Pathology				0.09†
Oligo-/atrophic	72	56 (77.8%)	16 (22.2%)	
Hypertrophic	66	58 (87.9%)	8 (12.1%)	
Infected	34	24 (70.6%)	10 (19.4%)	
Infection				0.13†
Not present	138	114 (82.6%)	24 (17.4%)	
Present	34	24 (70.6%)	10 (29.4%)	
No. prior orthopaedic operations				0.003†
0	16	14 (87.5%)	4 (12.5%)	
1	53	43 (81.1%)	10 (18.9%)	
2	48	45 (93.8%)	3 (6.2%)	
3+	55	36 (65.5%)	19 (34.5%)	
Hardware in situ during ESWT				0.11†
Yes	112	86 (76.8%)	26 (23.2%)	
No	60	52 (86.7%)	8 (13.3%)	
No. ESWT pulses delivered				0.04†
Less than 4000	71	52 (73.2%)	19 (26.8%)	
4000	53	48 (90.6%)	5 (9.4%)	
Greater than 4000	48	38 (79.2%)	10 (20.8%)	
ESWT treatments				0.002†
1	136	117 (86.0%)	19 (14.0%)	
2	26	17 (65.4%)	9 (34.6%)	
3	9	4 (44.6%)	5 (55.6%)	
4	1	0	1	
Number ESWT				<0.001†
1	136	117 (86.0%)	19 (14.0%)	
Greater than 1	36	21 (58.3%)	15 (41.7%)	
Time from injury to first ESWT treatment (months)				0.87*
Mean		12.7 ± 3.4	13.4 ± 4.8	
Time from last orthopaedic intervention to first ESWT treatment (months)				0.70*
Mean		8.46 ± 1.7	9.22 ± 2.84	
Time from injury to last follow up (months)				0.48*
Mean		19.9 ± 3.5	17.7 ± 5.2	
Time from last orthopaedic intervention to last follow up (months)				0.16*
Mean		15.6 ± 1.75	18.57 ± 3.68	

\*Analysis of variance.

†Contingency table analysis (JMP 7.0 statistical software).

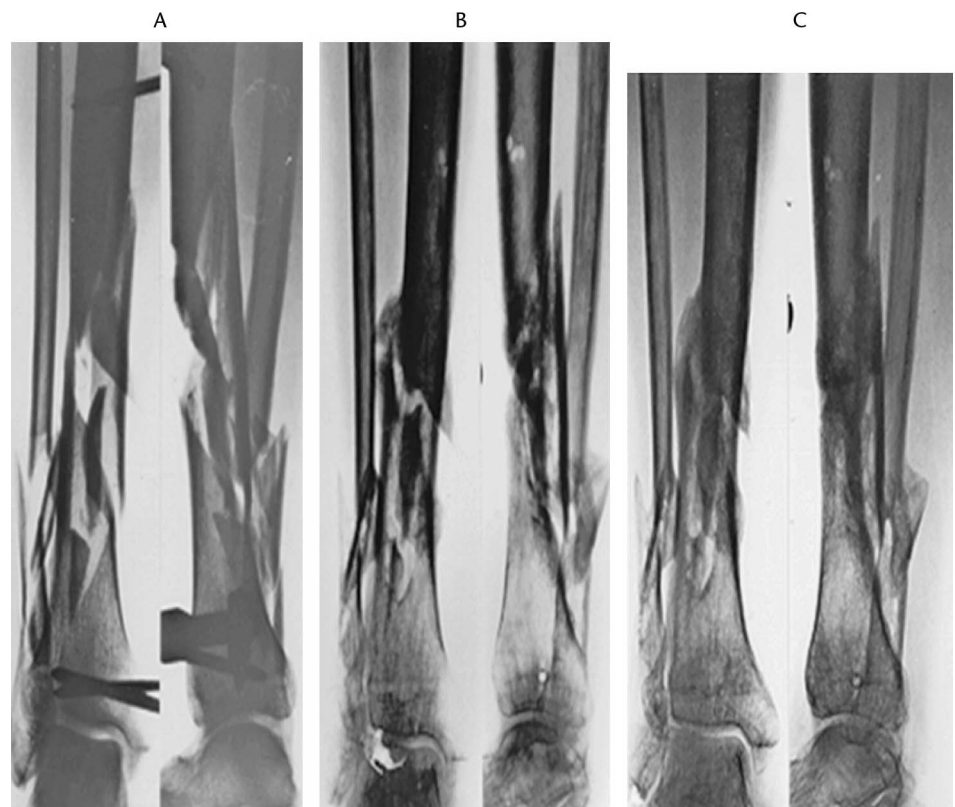
ESWT, extracorporeal shock wave therapy.



**FIGURE 2.** A 54-year-old diabetic woman with atrophic nonunion after a fall. Treated with one session of extracorporeal shock wave therapy and casting for 8 weeks. (A) Anterior–posterior (AP) and lateral views at 6 months. (B) AP and lateral views 3 months after treatment. (C) AP and lateral views 6 months after treatment.

were significantly associated with complete bone healing (Table 2). The significantly lower likelihood of fracture healing in patients requiring multiple (more than one) shock wave treatments versus a single treatment may be attributable to the

finding that a significantly greater proportion of patients with multiple rather than single ESWT treatments had three or more prior orthopaedic procedures (more than one ESWT, 63.9% versus one ESWT, 23.5%;  $P < 0.001$ ).



**FIGURE 3.** A 47-year-old man with hypertrophic nonunion after open fracture from a motorcycle accident. Treated with one session of extracorporeal shock wave therapy (ESWT) and casting. (A) Anterior–posterior (AP) and lateral views at time of injury. Treated in external fixator. (B) AP and lateral views 9 months after injury. (C) AP and lateral views four months after ESWT.

## DISCUSSION

Focused shock wave therapy has been used since the early 1990s in Europe and Asia for the treatment of nonunions with reported healing rates between 55% and 80%; however, this treatment modality has not gained widespread acceptance in the United States.<sup>25,41–43,45–48</sup> The current approach in the United States to this challenging problem focuses on initial control of infection, if present, followed by fracture stabilization, if indicated, and bone grafting augmented by recombinant bone morphogenic proteins or bone growth-stimulating devices such as ultrasound or electromagnetic devices. ESWT as well as ultrasound therapy and pulsed electromagnetic field stimulation are modalities that deliver targeted physical energy to produce the desired biologic effect of osseous healing. Although the exact mechanism underlying this mechanotransduction has yet to be elucidated precisely, migration and differentiation of mesenchymal stem cells and promotion of angiogenesis are thought to contribute increased bone mass and strength.<sup>34–39</sup>

Previous studies have reported 15 years' worth of clinical experience in Europe and Asia with ESWT for the treatment of fracture nonunions. These studies have been both retrospective and prospective in design and have included anywhere from 43 to 72 long bones treated with a variety of ESWT devices and varying degrees of posttreatment immobilization in heterogeneous populations. In contrast to studies reported using ultrasound or pulsed electromagnetic field stimulation, the patients in the ESWT studies underwent largely a single ESWT. The percentage of bony union, assessed by a combination of clinical and/or radiographic findings, after ESWT ranged from 55% to 87%. Our previously reported pilot study, which included 34 tibia fracture nonunions, demonstrated a healing rate of 76% and serves as the basis for the current study.<sup>42</sup>

This is the largest cohort of tibia nonunions reported to date treated at a single institution. The study was designed to assess the ability of ESWT to promote fracture union and restore limb function. In addition, we have attempted to elucidate the disease and treatment-related factors of prognostic significance in patients undergoing shock wave therapy for nonunion of the tibia. As such, we suggest that focused ESWT followed by fracture immobilization delivered in one brief treatment session (median total shock wave dose of 4000 pulses) in the majority of patients is associated with an 80% rate of nonunion healing as assessed by both clinical and radiographic means. These data suggest ESWT is both a safe and feasible treatment modality for tibia nonunion.

The study population consisted mainly of patients with tibia nonunion refractory to surgical treatment and/or immobilization (ie, negative selection bias). Median time to healing from last orthopaedic operation was 14 months with a mean follow-up period of nearly 16 months. The average time to healing after ESWT was 4.8 months. Follow up did not extend beyond documented nonunion healing in many cases, because these patients were treated under a Workmen's Compensation program and were released once treatment was completed and fracture healing and functional improvement documented. However, the follow-up time period in

this study represents a significantly longer follow-up period than previously reported in the literature with the majority of patients in this study demonstrating healing according to defined objective criteria within the first 6 months of shock wave treatment.<sup>45,49</sup> Despite the negative selection bias inherent in the study population, fracture healing 3 and 6 months after completion of shock wave therapy was 67% and 80%, respectively. Like with previously reported studies, fracture immobilization and stabilization were considered vital components of post-ESWT therapy and were incorporated into the study treatment protocol. Outcomes were unrelated to both the type ( $P = 0.60$ ) and duration ( $P = 0.32$ ) of post-ESWT immobilization. It is also important to note that although 33 patients in this series underwent concurrent ESWT orthopaedic procedures (eg, dynamization, hardware removal, external fixator placement), there was no difference in the rate of healing in this particular subset of patients ( $P = 0.54$ ).

The factors significantly associated with bony healing were related to number of treatment interventions. Increasing number of both orthopaedic operations before ESWT as well as number of postinjury shock wave treatments initiated after failed operation(s) correlated with failure of nonunion healing. Type, location, etiology, and pathology of nonunion as well as other treatment-related factors were not independently related to fracture healing. Like with our experience in treating soft tissue injuries with ESWT, early intervention before multiple treatment procedures was associated with greater therapeutic success than with delayed intervention with shock waves after demonstrated non-ESWT therapeutic futility. Multiple prior operative interventions for nonunion correlating with decreased success with ESWT likely relate to the severity of injury and/or periosteal disruption and impaired perfusion stemming from operative trauma. These findings suggest early referral and treatment with ESWT for nonunions may result in improved outcome and should serve as the basis for future controlled clinical trials.

Limitations of this study include those inherent to retrospective, nonrandomized study designs; however, its primary limitation is the lack of a control group to distinguish the effect of immobilization from the shock wave treatment itself. Related to the retrospective nature of the study is the loss of 20 patients to follow up. Although these patients were demographically similar to the remaining 172 patients, bias can be introduced in the analysis that may be ameliorated by a prospective study. A further limitation of this, and all studies concerning osseous nonunion, is the actual definition of "nonunion." Although not uniformly agreed on, our use of the 6-month criterion for defining nonunion was based on several factors. The local treatment practice guidelines in the standardized healthcare system in Austria limit the nonoperative management of nonunion to 6 months, therefore limiting our referral population to this time point. In addition, the 6-month definition of nonunion has been adopted by some regulatory bodies and provides further substantiation of the 6-month defining threshold used by our group.<sup>44</sup> Finally, as a result of the nature of our referral population, the antecedent treatment course was not controlled for but followed national standards of practice focused on surgical intervention and/or immobilization of the long-bone nonunion.



In summary, we describe the largest patient population reported to date treated successfully with ESWT for a representative group of tibia nonunions. These results were achieved in most cases with a single ESWT session coupled with standard-of-practice fracture immobilization techniques. Successful treatment outcome (healing of the nonunion) was associated with well-defined inherent predictive factors: frequency and intensity of both orthopedic and shock wave treatment. The most promising results arising from this study involve the treatment of atrophic nonunions. It is generally accepted that atrophic nonunions do not heal with immobilization alone, suggesting that the treatment effect seen in this subset of patients is a result of shock wave therapy.<sup>46-48</sup> This report adds to the growing body of literature, suggesting that physical energy delivered in the form of shock wave therapy has a direct biologic effect in promoting tissue and bone repair.<sup>49-53</sup> Mechanistic studies are underway to elucidate this effect.

### ACKNOWLEDGMENTS

We acknowledge the significant contributions of Drs. Andreas Fischer, Andreas Sailler, and Ender Karradas from the AUVA-Trauma Center in Meidling, Vienna. Their diligent care of this difficult patient population was critical to the work as presented herein.

### REFERENCES

- Praemer A, Furner S, Rice DP. *Musculoskeletal Conditions in the United States*. Rosemont, IL: American Academy of Orthopaedic Surgeons; 1999.
- Connolly JF. *Tibial Nonunion: Diagnosis and Treatment*. Park Ridge, IL: American Academy of Orthopaedic Surgeons; 1991.
- Friedlaender GE, Perry CR, Cole JD, et al. Osteogenic protein-1 (bone morphogenetic protein-7) in the treatment of tibial nonunions. *J Bone Joint Surg Am*. 2001;83(Suppl 1):S151-S158.
- Pheiffer LS, Goulet JA. Delayed unions of the tibia. *J Bone Joint Surg Am*. 2006;88:205-216.
- Gomberg BFC, Gruen GS, Smith WR, et al. Outcomes in acute orthopaedic trauma: a review of 130,506 patients by age. *Injury Int J Care Injured*. 1999;30:431-437.
- Swiontkowski MF, Chapman JR. Cost and effectiveness in care of injured patients. *Clin Orthop Relat Res*. 1995;318:17-24.
- Christian EP, Bosse MJ, Robb G. Reconstruction of large diaphyseal defects, without free fibular transfer in Grade IIIB tibial fractures. *J Bone Joint Surg Am*. 1989;71:994-1004.
- Blick SS, Brumback RJ, Lakatos R, et al. Early prophylactic bone grafting of high-energy tibial fractures. *Clin Orthop Relat Res*. 1989;240:21-41.
- Burgess AR, Poka A, Brumback RJ, et al. Pedestrian tibial injuries. *J Trauma*. 1987;27:596-601.
- Wiss DA, Sherman R, Oechsel M. External skeletal fixation and rectus abdominis free-tissue transfer in the management of severe open fractures of the tibia. *Orthop Clin North Am*. 1993;24:549-556.
- Wiss DA, Stetson WB. Unstable fractures of the tibia treated with a reamed intramedullary interlocking nail. *Clin Orthop Relat Res*. 1995; 315:56-63.
- Wiss DA, Stetson WB. Tibial nonunion: treatment alternatives. *J Am Acad Orthop Surg*. 1996;4:249-257.
- Johnson EE, Urist MR, Finerman GA. Persistent nonunions and partial or complete segmental defects of long bones. Treatment with implants of a composite of human bone morphogenetic protein (BMP) and autolyzed, antigen-extracted, allogeneic (AAA) bone. *Clin Orthop Relat Res*. 1992; 277:229-237.
- Delloe C, Suratwala SJ, Cornu O, et al. Treatment of allograft nonunions with recombinant human bone morphogenetic proteins (rhBMP). *Acta Orthop Belg*. 2004;70:591-597.
- Jones AL, Bucholz RW, Bosse MJ, et al. Recombinant human BMP-2 ad allograft compared with autogenous bone graft for reconstruction of diaphyseal tibial fractures with cortical defects. *J Bone Joint Surg Am*. 2006;88:1431-1441.
- Patil S, Montgomery R. Management of complex tibial and femoral nonunion using the Ilizarov technique and its cost implications. *J Bone Joint Surg Br*. 2006;88:928-932.
- Ashok G, Sangwan SS, Siwach RC, et al. Percutaneous bone marrow grafting for the treatment of tibial non-union. *Injury Int J Care Injured*. 2005;36:203-206.
- Heckman JD, Ingram AJ, Loyd RD, et al. Nonunion treatment with pulsed electromagnetic fields. *Clin Orthop Relat Res*. 1981;161:58-66.
- Delima DF, Tanna DD. Role of pulsed electromagnetic fields in recalcitrant non-unions. *J Postgrad Med*. 1989;35:43-48.
- Meskens MW, Stuyck JA, Feys H, et al. Treatment of nonunion using pulsed electromagnetic fields: a retrospective follow-up study. *Acta Orthop Belg*. 1990;56:483-488.
- Garland DE, Moses B, Salyer W. Long-term follow-up of fracture nonunions treated with PEMFs. *Contemp Orthop*. 1991;22:295-302.
- Nolte PA, van der Krans A, Patka P, et al. Low-intensity pulsed ultrasound in the treatment of nonunions. *J Trauma*. 2001;51:693-702.
- Gebauer D, Mayr E, Orthner E, et al. Low-intensity pulsed ultrasound: effects on nonunions. *Ultrasound Med Biol*. 2005;31:1391-1402.
- Heckman JD, Ryaby JP, McCabe J, et al. Acceleration of tibial fracture-healing by non-invasive, low-intensity pulsed ultrasound. *J Bone Joint Surg Am*. 1994;76:26-34.
- Rompe JD, Zoellner J, Nafe B. Shock wave therapy versus conventional surgery in the treatment of calcifying tendinitis of the shoulder. *Clin Orthop Relat Res*. 2001;387:72-82.
- Wang CJ, Yang KD, Wang FS, et al. Shock wave therapy for calcific tendinitis of the shoulder: a prospective clinical study with two-year follow-up. *Am J Sports Med*. 2003;31:425-430.
- Rompe JD, Decking J, Schoellner C, et al. Shock wave application for chronic plantar fasciitis in running athletes. A prospective, randomized, placebo-controlled trial. *Am J Sports Med*. 2003;31:268-275.
- Cosentino R, De Stefano R, Selvi E, et al. Extracorporeal shock wave therapy for chronic calcific tendinitis of the shoulder: single blind study. *Ann Rheum Dis*. 2003;62:248-250.
- Melikyan EY, Shahin E, Miles J, et al. Extracorporeal shock-wave treatment for tennis elbow. A randomised double-blind study. *J Bone Joint Surg Br*. 2003;85:852-855.
- Thomson CE, Crawford F, Murray GD. The effectiveness of extra corporeal shock wave therapy for plantar heel pain: a systematic review and meta-analysis. *BMC Musculoskelet Disord*. 2005;6:19.
- Spacca G, Necozone S, Cacchio A. Radial shock wave therapy for lateral epicondylitis: a prospective randomised controlled single-blind study. *Eura Medicophys*. 2005;41:17-25.
- Cacchio A, Paoloni M, Barile A, et al. Effectiveness of radial shock-wave therapy for calcific tendinitis of the shoulder: single-blind, randomized clinical study. *Phys Ther*. 2006;86:672-682.
- Kudo P, Dainty K, Clarfield M, et al. Randomized, placebo-controlled, double-blind clinical trial evaluating the treatment of plantar fasciitis with an extracorporeal shockwave therapy (ESWT) device: a North American confirmatory study. *J Orthop Res*. 2006;24:115-121.
- Wang CJ, Yang KD, Wang FS, et al. Shock wave treatment shows dose-dependent enhancement of bone mass and bone strength after fracture of the femur. *Bone*. 2004;34:225-230.
- Rompe JD, Kirkpatrick CJ, Kullmer K, et al. Dose-related effects of shock waves on rabbit tendo Achilles. A sonographic and histological study. *J Bone Joint Surg Br*. 1998;80:546-552.
- Wang CJ, Huang HY, Pai CH. Shock wave-enhanced neovascularization at the tendon-bone junction: an experiment in dogs. *J Foot Ankle Surg*. 2002;41:16-22.
- Wang CJ, Wang FS, Yang KD, et al. Shock wave therapy induces neovascularization at the tendon-bone junction. A study in rabbits. *J Orthop Res*. 2003;21:984-989.
- Wang FS, Wang CJ, Sheen-Chen SM, et al. Superoxide mediates shock wave induction of ERK-dependent osteogenic transcription factor (CBFA1) and mesenchymal cell differentiation toward osteoprogenitors. *J Biol Chem*. 2002;277:10931-10937.
- Wang FS, Wang CJ, Chen YJ, et al. Ras induction of superoxide activates ERK-dependent angiogenic transcription factor HIF-1alpha and VEGF-A



- expression in shock wave-stimulated osteoblasts. *J Biol Chem*. 2004;279:10331–10337.
40. Rompe JD, Rosendahl T, Schollner C, et al. High-energy extracorporeal shock wave treatment of nonunions. *Clin Orthop Relat Res*. 2001;387:102–111.
  41. Wang CJ, Chen HS, Chen CE, et al. Treatment of nonunions of long bone fractures with shock waves. *Clin Orthop Relat Res*. 2001;387:95–101.
  42. Schaden W, Fischer A, Sailler A. Extracorporeal shock wave therapy of nonunion or delayed osseous union. *Clin Orthop Relat Res*. 2001;387:90–94.
  43. Wiss DA, Stetson WB. Tibial nonunion: treatment alternatives. *J Am Acad Orthop Surg*. 1996;4:249–257.
  44. Schoelles K, Snyder D, Kaczmarek J, et al. *The Role of Bone Growth Stimulating Devices and Orthobiologics in Healing Nonunion Fractures*. Agency for Healthcare Research and Quality. September 2005. Available at: <http://www.cms.hhs.gov/determinationprocess/downloads/id29TA.pdf>.
  45. Weber BG, Cech O. *Pseudoarthrosis: Pathology, Biomechanics, Therapy, Results*. Berne, Switzerland: Hans Huber Medical Publisher; 1976.
  46. Sarmiento A, Burkhalter WE, Latta LL. Functional bracing in the treatment of delayed union and nonunion of the tibia. *Int Orthop*. 2003;27:26–29.
  47. Sarmiento A, Latta LL. *Closed Functional Treatment of Fractures*. Berlin: Springer-Verlag; 1981:1–58.
  48. Mayr E, Frankel V, Ruter A. Ultrasound—an alternative healing method for nonunions? *Arch Orthop Trauma Surg*. 2000;120:1–8.
  49. Valchanou VD, Michailov P. High energy shock waves in the treatment of delayed and nonunion of fractures. *Int Orthop*. 1991;15:181–184.
  50. Vogel J, Hopf C, Eysel P, et al. Application of extracorporeal shock-waves in the treatment of pseudoarthrosis of the lower extremity. Preliminary results. *Arch Orthop Trauma Surg*. 1997;116:480–483.
  51. Biedermann R, Martin A, Handle G, et al. Extracorporeal shock waves in the treatment of nonunions. *J Trauma*. 2003;54:936–942.
  52. Gerdesmeyer L, von Eiff C, Horn C, et al. Antibacterial effects of extracorporeal shock waves. *Ultrasound Med Biol*. 2005;31:115–119.
  53. Schaden W, Thiele R, Köpl C, et al. Shock wave therapy for acute and chronic soft tissue wounds: a feasibility study. *J Surg Res*. 2007;143:1–12.